SAGES 2026

MARCH 25-28, 2026 | TAMPA CONVENTION CENTER | TAMPA, FL

SURGEON–RADIOLOGIST CONCORDANCE IN IMAGING INTERPRETATION OF COMPLEX VENTRAL HERNIAS:

IMPLICATIONS FOR SURGICAL PLANNING

P. HUCHIM [1], V. MOSQUEDA [1], C. GAMBOA [1], L. MARTIN DEL CAMPO [2,3], A. ESPINOSA DE LOS MONTEROS [1].

1 National Institute of Medical Sciences and Nutrition Salvador Zubirán; Mexico City , Mexico, 2 Western Center for Esophageal Diseases. Hospital Real San Lucas. Tepatitlán, Jalisco, Mexico, 3 Robotic Surgery Center. Hospital Ángeles Andares. Guadalajara, Jalisco, Mexico.

INTRODUCTION

Preoperative planning for complex ventral hernia relies heavily on **imaging interpretation**. However, **surgeons and radiologists** often use **different descriptive frameworks,** potentially leading to **discrepancies** in diagnosis, surgical approach selection, and risk stratification. The extent of this disagreement has not been systematically evaluated. This study aimed to assess the concordance between surgical and radiological interpretations.

MATERIAL & METHODS

We conducted a **cross-sectional analytical study** at a tertiary referral center including patients with complex ventral hernias operated between 2017 and 2023, all with preoperative CT scans. Variables assessed included hernia size, anatomical location, number of defects, and presence of rectus diastasis. Agreement was analyzed using **Cohen's kappa and the intraclass correlation coefficient (ICC).**

RESULTS

A total of **101 patients** were analyzed (51.1% female; median age 58 years; mean BMI 28.7 kg/m²). The most common comorbidities were obesity (39.6%) and hypertension (33.7%). Concordance for **anatomical location was minimal** (κ = 0.374; 95% CI 0.235–0.513). **Identification of rectus diastasis demonstrated no agreement** (κ = −0.047; 95% CI −0.078 to −0.015). Concordance for **number of hernias was also minimal** (κ = 0.214; 95% CI 0.059–0.369). **Quantitative measurements showed poor reliability** (ICC = −0.027; 95% CI −0.220 to 0.168).

Surgeons and radiologists interpret complex ventral hernia CT scans differently.

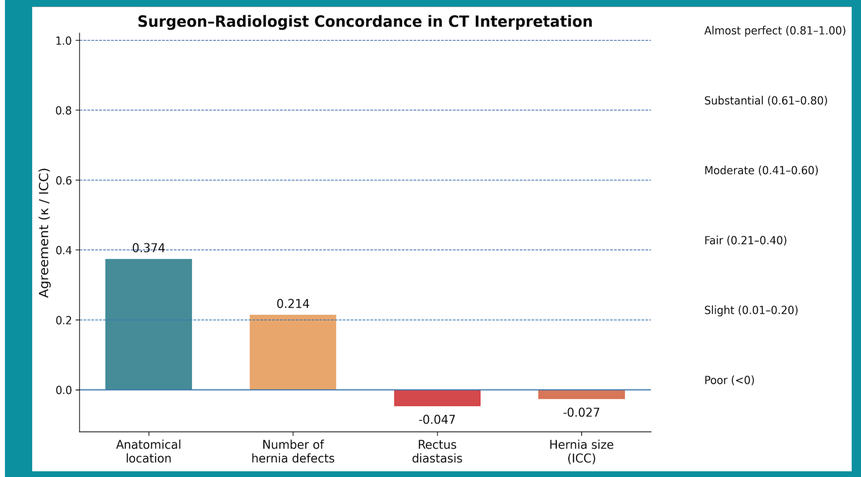

Poor agreement was particularly evident for rectus diastasis and quantitative measurements.

Table 2. Baseline Characteristics of the Study Population (n = 101)

Variable	Value
Female sex	52 (51.1%)
Age, median (years)	58
BMI, mean (kg/m²)	28.7
Obesity	40 (39.6%)
Hypertension	34 (33.7%)

Table 3. Hernia Characteristics Evaluated on Preoperative CT

Variable Evaluated	Description
Hernia anatomical location	Midline, lateral, or combined defects
Number of hernia defects	Single or multiple defects
Rectus diastasis	Presence or absence of rectus muscle separation
Hernia size	Quantitative measurement of the fascial defect on CT

CONCLUSIONS

There is poor agreement between surgical and radiological interpretations of complex ventral hernia imaging, particularly for rectus diastasis and quantitative measurements. **Standardized multidisciplinary imaging criteria** between surgeons and radiologists are **needed to improve preoperative planning in complex ventral hernia repair.**

CONTACT INFORMATION

Paulina Huchim

Mail: pauhs99@gmail.com