EARLY ABDOMINAL ECTOPIC PREGNANCY:DIAGNOSIS AND MANAGEMENT

Memon Zaibunnissa, Khan Aqsa Arbab, Shireen Farhat, Hemrich Mira, Dafalla Elamin.

Introduction

Abdominal ectopic pregnancy may be primary or secondary. In Primary Abdominal Pregnancy, there is direct implantation of blastocyst into the abdominal cavity. Secondary Abdominal Pregnancy may occur due to tubal abortion or tubal rupture. Abdominal pregnancy is further classified as early or advanced. Early abdominal pregnancy when diagnosed at or before 20weeks of gestation, while advanced abdominal pregnancy is diagnosed after 20 weeks of gestation. Risk factors may include use of progesterone pills, IUCDs, previous pelvic surgery, Sexually Transmitted Infections (STI's) and Assisted Reproduction Technique (ART). Clinical presentation is very non-specific, but most frequently include abdominal pain, missed or irregular periods with gastrointestinal symptoms such as nausea and vomiting. Diagnosis is made by transvaginal ultrasound, MRI, or intraoperatively during surgical exploration. Most patients diagnosed at the time of surgery.

Case Report

A 44-year-old woman, $G_5P_3^{+1}$, with previous all vaginal deliveries (youngest 12yrs old), presented via ambulance to Accident and Emergency (A&E) with complain of lower abdominal pain for one week, along with nausea and vomiting for a day. Her LMP was unsure due to irregular periods (not aware of pregnancy) and not on any contraception. No significant medical/surgical history apart from appendectomy. On examination of urine pregnancy test was positive, haemodynamically she was stable (BP:104/51 mmHg, Pulse:72/ minute, RR:18/ minute, Temperature:36.8 C, Spo2:98%). Abdomen distended with mild tenderness. Patient transferred to Gynaecology ward withy possible ectopic pregnancy. Bloods done in A&E which revealed HB:10.8, WBCS:14.6, N:12.13, CRP:22.25, BHCG: 71233 IU/L. Transvaginal Ultrasound bedside showed viable 10+3 weeks pregnancy in Right adnexa/ cornual pregnancy (FIG 1) separated from right ovary which appears normal empty uterine cavity (FIG 2), along with hemoperitoneum, the left ovary not visualized.

FIG 1: EXTRAUTERINE/COURNUAL PREGNANCY (VIABLE PREGNANCY, CRL~10+3WKS)

FIG 2: EMPTY UTERINE CAVITY & BLOOD CLOTS SEEN

Urgent laparotomy was decided revealed pregnancy with gestational sac with the placenta adherent to right fallopian tube, pelvic wall and rectum, and 1.7 litre of hemoperitoneum, gestational sac removed intact along with foetus and placenta (FIG 3 & FIG 4) from adjacent structures and right salpingectomy done. Surgical team involved due to the bleeding from bowel serosa and colonoscopy done which appeared normal. Haemostasis secured by application of topical haemostatic agents (haemostatic powder and surgical). Patient did not receive blood transfusion. She was hemodynamically stable; the patient made a good recovery, and she was discharged from the hospital on day 5. BHCG followed weekly until less than 5 IU/L. Histopathology revealed a ruptured haemorrhagic fallopian tube measuring 9 x 3 x 4 cm with adjacent blood clot and placental tissue comprising chorionic villi and foetal membranes.

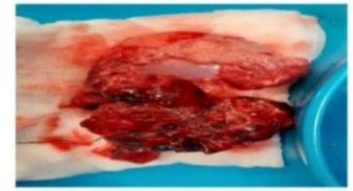

FIG 3: INTACT GESTATIONAL SAC WITH F AND PLACENTA

FIG 4: FOETUS

Discussion

Surgery is the most common method of management of abdominal ectopic pregnancy. Laparoscopy or Laparotomy is preferred to laparoscopic surgery because of large hemoperitoneum, high risk of uncontrollable bleeding.

Conclusion

Early and accurate diagnosis of abdominal ectopic pregnancy is important to minimize morbidity and morality associated with this potentially life-threatening condition.

References

1. Hung Q.N. and Nguyen T.H. (2021). Abdominal pregnancy: visual encyclopedia of ultrasound in Obstetrics and Gynecology. Available from: www.isuog.org
2. Suneet P.C. and Asha B.B. (2024). Abdominal pregnancy, UpToDate [online]. Available from: https://www.uptodate.com/contents/abdominal-pregnancy/print
3. Ahmed H., Dhekra T., Ons L., On C. and Raja F. (2020). Early primary abdominal pregnancy: diagnosis and management, a case report. ELSEVIERE [online], International Journal of Surgery Case Reports 73, pp. 303-306. Available from: https://doi.org/10/1016/j.ijscr.2020.07.048
4. Paul N.T., Martin H.A., Jacqueline Z.M. and Eugene B.P. (2017). The challenge in the diagnosis and management of an advanced abdominal pregnancy in a resource-low setting: a case report. BioMedCentral [online], Journal of Medical Case Reports 11:199. Available from: https://DOI10.1186/s13256-017-1369-1