Emergent thoracotomy and diagnostic laparoscopy secondary to multiple stab wounds in the chest and abdomen followed by serratus anterior block for pain management

Bintia Sakho MD[1], Alexandra Solowinska BS, MA[2], Ehab Al Bizri MD[1]

1. Department of Anesthesiology, 2. Renaissance School of Medicine, Stony Brook University, Stony Brook, NY, 11794

INTRODUCTION

Effective analgesia in thoracoabdominal trauma is essential to prevent respiratory compromise and facilitate recovery. Gold standard techniques such as epidural or paravertebral blocks, while effective, may be contraindicated in patients with penetrating injuries or infection risk near the spine. The serratus anterior plane (SAP) block provides a safe, ultrasound-guided alternative that offers effective unilateral thoracic analgesia with few complications.

Case Description

- 15-year-old male presented as Level 1 trauma after eight stab wounds to the left chest and flank with evisceration.
- Prehospital needle decompression performed for suspected tension pneumothorax.
- On arrival, patient was hypotensive with 1L chest tube output, prompting activation of the massive transfusion protocol.
- Intubated and underwent left thoracotomy with lower lobe wedge resection and exploratory laparotomy revealing omental herniation without visceral injury.
- Interventional radiology embolized three bleeding intercostal arteries.
- In the PICU, patient was sedated and weaned to 40% FiO_2.
- On POD1, serratus anterior plane block provided immediate pain relief and improved pulmonary function.
- Incentive spirometry volumes improved from 1000 mL to 3000 mL, and the patient transitioned from high-flow nasal cannula to room air within 24 hours, demonstrating marked improvement in pulmonary function.

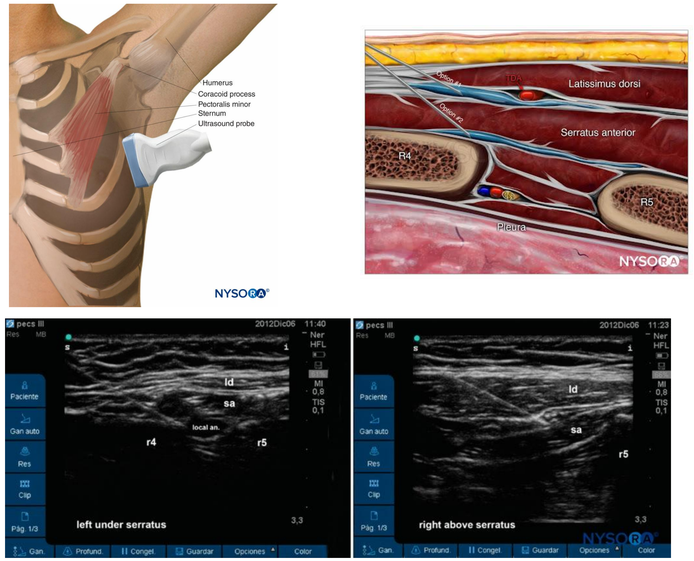

Fig 1: transducer positioning, fig 2-3: possible location of SAP block

Fig 4-5: Ultrasound image of SAP block in patient

Discussion

Trauma, cardiac, and thoracic surgeries are frequently associated with significant postoperative pain, which can compromise respiratory mechanics and increase the risk of pulmonary complications and morbidity.[1] To mitigate these risks, the implementation of a comprehensive multimodal analgesic regimen—often incorporating regional anesthesia—is critical for achieving effective pain control and enhancing recovery.

The serratus anterior plane (SAP) block is a regional technique that targets the hemithorax by depositing local anesthetic superficial or deep to the serratus anterior muscle, typically between it and the latissimus dorsi. This approach aims to anesthetize the lateral cutaneous branches of the intercostal nerves (T2–T9), as well as the long thoracic, thoracodorsal, and intercostobrachial nerves.[2]

SAP blocks have demonstrated efficacy in providing thoracic analgesia across various clinical scenarios, including thoracoscopy, breast surgery, rib fractures, and shoulder procedures.[2-3] Multiple studies report that SAP blocks are associated with reduced postoperative opioid requirements and improved patient comfort following thoracic surgery.[2-3]

While thoracic epidural and paravertebral blocks are often considered the gold standard for thoracic analgesia, their use may be limited in the presence of trauma, infection, or altered anatomy at or near the injection site. In such contexts, the SAP block offers a less invasive and potentially safer alternative.[3]

References

1. Jack JM, McLellan E, Versyck B, Englesakis MF, Chin KJ. The role of serratus anterior plane and pectoral nerves blocks in cardiac surgery, thoracic surgery and trauma: a qualitative systematic review. Anaesthesia. 2020;75(10):1372-1385. doi:10.1111/anae.15000

2. Liu X, Song T, Xu H-Y, et al. The serratus anterior plane block for analgesia after thoracic surgery: A meta-analysis of randomized controlled trials. Medicine. 2020;99(21):e20286. doi:10.1097/MD.0000000000020286

3. Mayes J, Davison E, Panahi P, et al. An anatomical evaluation of the serratus anterior plane block. Anaesthesia. 2016;71(9):1064-1069. doi:10.1111/anae.13549

Figure 1-3 : credit NYSORA