Typical L2L3 and L3L4 Interspinous Space Dimensions: Details That Help Guide Epidural Insertion

Sue Lawrence[1,2,3], Nicole Atcheson[1], David Reutens[1,2,3], David Sturgess[2,4]

[1] Centre for Advanced Imaging, Australian Institute of Bioengineering and Nanotechnology, The University of Queensland, Australia
[2] Faculty of Health, Medicine and Behavioural Sciences, The University of Queensland
[3] Royal Brisbane and Women's Hospital, Brisbane, Australia
[4] Princess Alexandra Hospital, Brisbane, Australia

Introduction

Midline translaminar insertion of a lumbar spinal or epidural is a simple procedure until it is not.[1] This morphometric summary assists to inform needle advancement, redirections and sonogram interpretation.

Methods

Ethics approval was obtained for examination and magnetic resonance imaging (MRI) of the lumbar spines of healthy young adults (18 – 20 years). MRI measurements were taken from a midline, mid-interspinous space axis for each interspace (T12L1-L5S1). Values are given as mean and standard deviation (m, sd).

Results

The 27 volunteers (16 female, 11 male) were found to have normal lumbar anatomy.

L3L4 was the modal and highest level of the intercristal line (66.7%, n = 18). Overlying subcutaneous tissue thickness had the greatest variation between individuals (19.3, 10 mm) with a minimum of 5.1mm and maximum 50.1mm. Mean subcutaneous tissue thickness at the L2L3 interspace (16.3, 8.3 mm) was less than the L3L4 interspace (22.2, 11.0 mm). See Table for other dimensions.

Paired ligamenta flava leaves centrally abutted creating an acute angle and form the posterolateral boundaries of the inverted triangular prism of the posterior epidural space segment.

The mean posterior epidural space segment had a volume approximating 0.3ml.

Deep to the posterior epidural space segment, the mean thickness of the whole vertebral canal was 22.0 mm (sd 1.9 mm). Mean thecal sac width was 19.4 mm (sd 0.1 mm). Just lateral to the posterior epidural space segment the dura mater appeared to be closely related to the anterior surface of the ligamentum. The majority (77.8%, n = 42) of vertebral interspaces were widest at the interlaminar space as compared with supraspinous ligament width.

Sue.Lawrence@uqconnect.edu.au

Figure: Approximate L2L3 & L3L4 Needle Distances

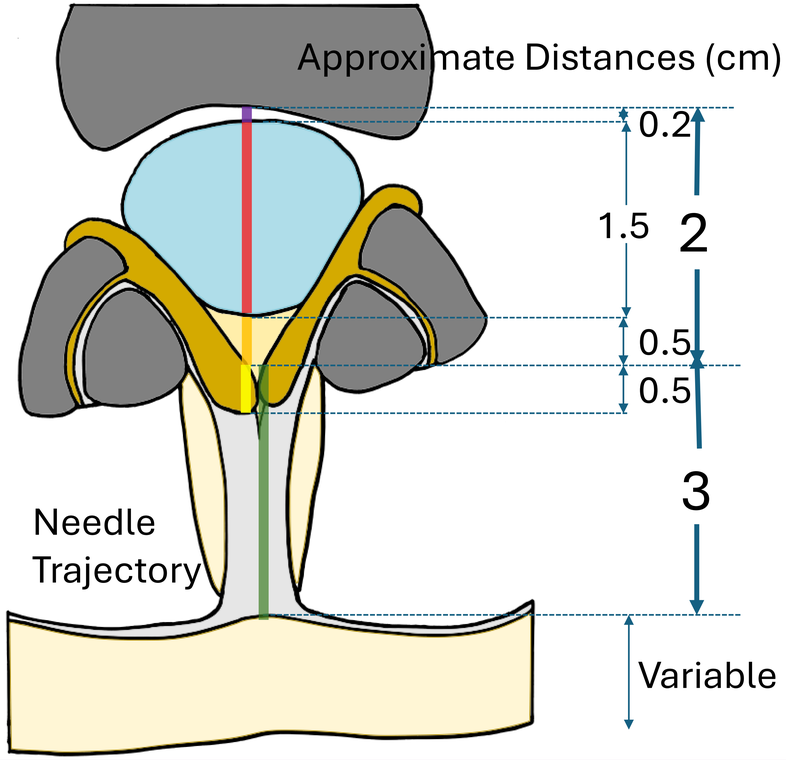

Table: L2L3 and L3L4 Combined Dimensions

	Measurement	Mean (mm)	sd (mm)
Supraspinous Ligament through Interspinous Ligament and Ligamentum Flavum	Length	32.2	4.6
Ligamentum Flavum	Thickness	5.3	1.8
Posterior Epidural Space Segment	Thickness	6.1	1.3
Thecal Sac	Thickness	14.4	0.2
Anterior Epidural Space	Thickness	1.7	0.2
Interspinous Space –Posterior	Height	11.3	2.8
Interspinous Space –Minimum	Height	9.8	2.3
Interlaminar Space	Height	13.2	2.6
Interspinous Space –Posterior	Width	7.4	2.6
Interlaminar Space	Width	11.1	4.1
Interlaminar Space Edge to Facet Joints	Separation	9.8	2.8
Facet Joint to Ligamentum Flavum Posterior Margin	Separation	1.3	2.7

Discussion

By reacquainting a clinician with precise anatomical terms, form, orientation, and relationships, ultrasonographic image interpretation and real-time sensing of needle tip location may be improved.

This information may be used when observing a trainee, after a spinous process is tipped by a needle in a difficult to palpate individual, estimating needle length adequacy, or when a CSE is attempted in cases with expanded epidural space and so contracted intrathecal space volumes.

Interlaminar Space =

The bony gap occupied by the Ligamentum Flavum,

Width ~ 1cm
wider inferiorly and lower interspaces

Effective Height ~ 1 cm midline
~ 1.3 cm paramedian approach

References

1 Knight M, Kurinczuk JJ, Spark P, Brocklehurst P, System UKOS. Extreme obesity in pregnancy in the United Kingdom. Obstet Gynecol. 2010;115(5):989-97.

Acknowledgements

Helen Hunt for statistical advice.

Funded using CAI Confirmation Fund.

THE UNIVERSITY OF QUEENSLAND AUSTRALIA

CREATE CHANGE

CRICOS 00025B • TEQSA PRV12080