ISUOG WORLD CONGRESS
14–17 SEPTEMBER 2025
CANCUN, MEXICO

Instituto Nacional de Perinatología
Isidro Espinosa de los Reyes

EP05.13. First-trimester prenatal diagnosis of OEIS complex and postnatal association with deletion 4p16: case report

Ana Jimena Lopez-Diaz[1] MD, Sandra Acevedo-Gallegos[1] MD, MSc, PhD, Larissa Lopez-Rodriguez[2] MD, Juan Manuel Gallardo-Gaona[1] MD, MSc, PhD, Maria J. Rodriguez-Sibaja[1] MD, Mario I. Lumbreras-Marquez[1] MD, MSc, Yazmin Copado-Mendoza[1] MD, MSc, Berenice Velazquez-Torres[1] MD, MSc, José Antonio Ramirez-Calvo[1] MD, MSc, Dulce Maria Camarena-Cabrera[1] MD, MSc, Yubia Amaya-Guel[1] MD, MSc

1. Maternal-Fetal Medicine, Instituto Nacional de Perinatologia, Mexico City, Mexico. 2. Perinatal Genetics, Instituto Nacional de Perinatologia, Mexico City, Mexico

Introduction

OEIS complex is a rare midline defect comprising omphalocele, cloacal exstrophy, imperforate anus, and spinal and genital anomalies, with an incidence of 1 in 200,000 to 400,000 pregnancies. The etiology remains unknown, in rare cases, association with genetic causes such as copy number variants (CNV) have been identified (1p361 deletion, 9q34.1-qter, 3q12.2-3q13.2), with no recurrent variant reported. Wolf-Hirschhorn syndrome (WHS) results from a 4p16.3 deletion and presents with multiple anomalies, many related to midline fusion defects, skeletal abnormalities (50–75%), and genitourinary malformations (25–50%), aligning with the OEIS complex phenotype. However, an association between OEIS complex and 4p16 deletion has not been previously described.

Case report

We present a first-trimester prenatal diagnosis of OEIS complex associated with 4p16.3 deletion (WHS). First-trimester screening was performed in a 34-year-old woman at 11 4/7 weeks' gestation with evidence of abdominoschisis with protrusion of intra-abdominal organs, megacystis, single left umbilical artery, non-assessable genitalia, a lumbosacral defect with a sac-like structure, and bilateral equinovarus feet. Pregnancy termination was performed, and a 140-gram fetus was delivered, confirming the prenatal ultrasound findings. MLPA genetic study for aneuploidies (SALSA 070) and microdeletions (SALSA 245) reported a deletion in chromosome 4p16.

Conclusion

This case displays the relevance of prenatal diagnosis of OEIS complex for accurate parental counseling and a multidisciplinary approach to identifying associated genetic conditions and recurrence risks, so it is suggested to continue studying and reporting these cases.

Figure 1. Sagital view of abdominal wall defect

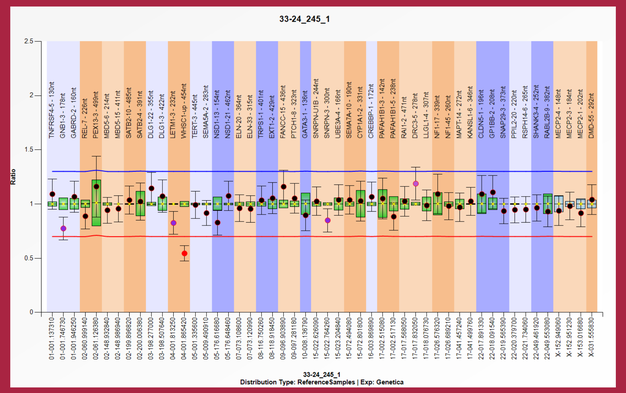

Figure 2. MLPA genetic study with deletion in 4p16