Recurrent *Parvimonas micra* Infection: From Lumbar Osteomyelitis to Hip Prosthetic Joint Infection in a Patient with Cirrhosis

Kathleen Miller, MD, Morgan Freiman, MD MPH, Phil Aurigemma, MD, Stephanie Clegg, MD
Lahey Clinic Infectious Disease and Orthopedic Surgery

Background

- *Parvimonas micra* is an anaerobic Gram-positive coccus that rarely causes prosthetic joint infection (PJI).
- It typically presents with an indolent clinical course, making diagnosis challenging.
- We report recurrent *P. micra* infection involving prior lumbar instrumentation and a prosthetic hip occurring **6 years after the initial infection**.

Discussion

- **Late recurrence:** Identical anaerobic organism recovered six years after initial spinal infection suggests chronic spinal hardware infection rather than a new infection.
- **Diagnostic challenge:** P. micra may present indolently and initially mimic aseptic prosthetic failure
- **Microbiologic considerations:** Prolonged anaerobic incubation and molecular diagnostics may improve detection of anaerobic pathogens
- **Management:** source control with revision arthroplasty and prolonged antibiotic course

Case Timeline

Date	Clinical Event
December 2019	Lumbar osteomyelitis due to *P micra* --> L1-L2 decompression and hardware placement + 6 months total antibiotics (completed May 2020)
October 2025	Progressive R hip pain, fevers, night sweats
November 2025	Imaging with large RP abscess tracking to hip and spine --> cultures grew *P micra* --> first stage of two stage revision arthroplasty with articulating antibiotic spacer placed + RP abscess drainage, received 6 weeks IV antibiotics and then 3 months oral antibiotics
April 2026	Re-aspiration of R hip off antibiotics, negative cultures
May 2026	Stage 2 re-implantation of new R hip arthroplasty

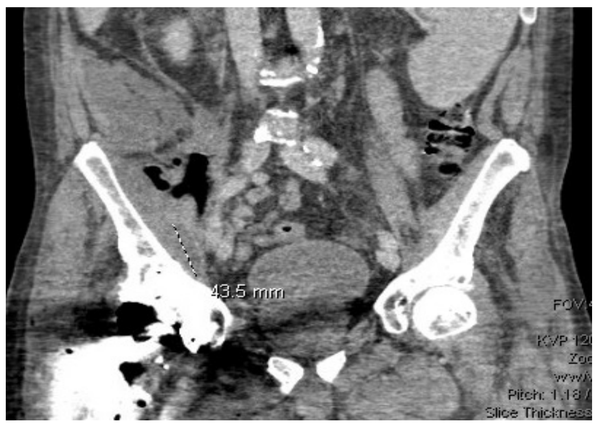

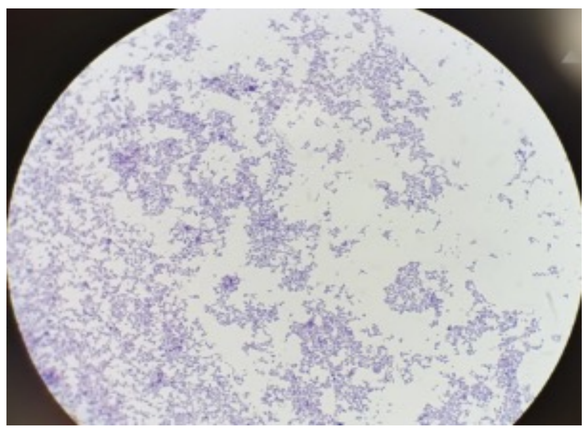

Key Take-Home Messages

✓ Consider ***Parvimonas micra*** in late, culture-negative, or indolent prosthetic joint infections.
✓ Evaluate prior spinal instrumentation as a potential source when spinal and prosthetic joint infections coexist.
✓ Adequate anaerobic culture techniques and advanced molecular diagnostics can improve pathogen identification.
✓ Successful management requires both surgical source control and prolonged targeted antimicrobial therapy.