Real-World Oritavancin PK-Guided Suppressive Therapy for Chronic Non-*faecalis* Enterococci Prosthetic Joint and Fracture-Related Infections: A Case Series from a Reference Centre

Petri Francesco[1], Scandiffio Letizia[2], Montagna Carlo[3], De Capitani Giovanni[3], Cattaneo Dario[4, 5], Landonio Simona[1], Merli Stefania[1], Coen Massimo[1], Dolci Alberto[2,3], Gori Andrea[1,3], Passerini Matteo[1]

1. Department of Infectious Diseases, ASST Fatebenefratelli Sacco, Luigi Sacco University Hospital, Regional Centre for Infectious Diseases (CEREMI), Milan, Italy.
2. Laboratory of Clinical Microbiology, Virology and Bioemergencies, ASST Fatebenefratelli Sacco, Luigi Sacco Hospital, Milano, Italy.
3. Department of Biomedical and Clinical Sciences, Università degli Studi di Milano, Milano, Italy;
4. Department of Biomedical Sciences, Humanitas University, Pieve Emanuele, Italy.
5. IRCCS Humanitas Research Hospital, Milan, Italy.

Background. Suppressive antibiotic treatment (SAT) for prosthetic joint infections (PJIs) or fracture-related infections (FRIs) due to non-*faecalis* enterococci remains challenging. Long-acting lipoglycopeptides such as oritavancin may facilitate outpatient management, yet real-world experience is limited, especially for therapeutic drug monitoring (TDM)-guided administration. We describe the first four off-label oritavancin cases treated at our referral centre.

Methods. Clinical, laboratory, tolerability, and PK data were collected prospectively during oritavancin therapy for non-*faecalis* enterococci isolated from intraoperative deep bone cultures. Oritavancin was administered as 1200 mg on days 1 and 8, with TDM monitoring, and then weekly. Multiple serial PK samples (including C_{min} and C_{max}) were collected for each infusion up to 72-hour post-dose when feasible.

Figure 1 – PK profiles of TDM-guided oritavancin for Patient 1.

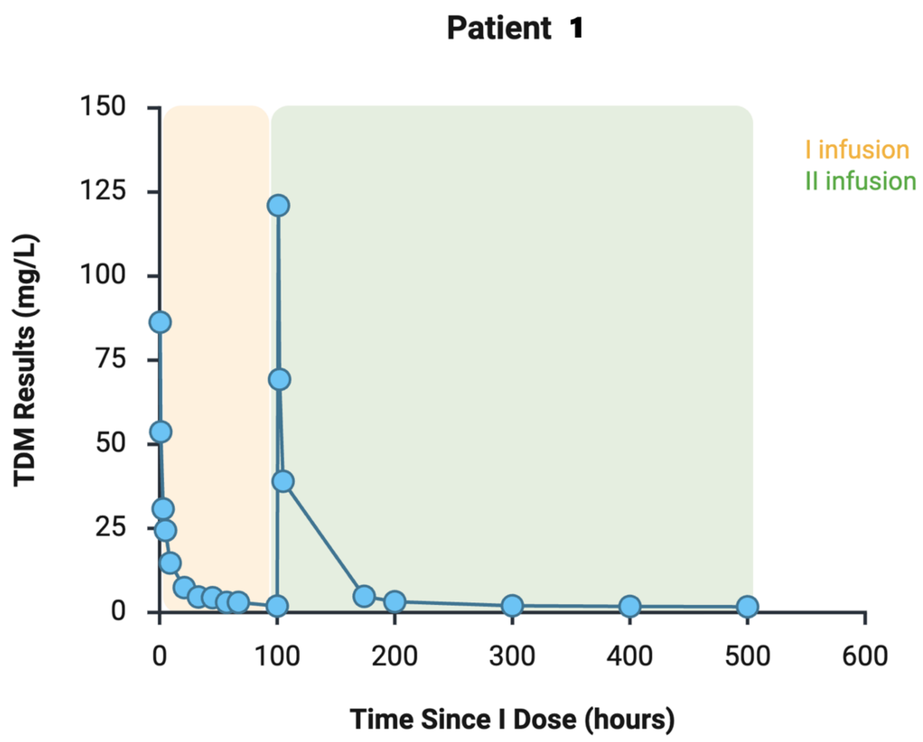

Figure 2 – PK curve of the administration of TDM-guided oritavancin for Case 2. Red arrows indicate the timing of the administration of the drug. The red line indicates the suggested threshold for plasmatic target attainment suggested by some experts (1).

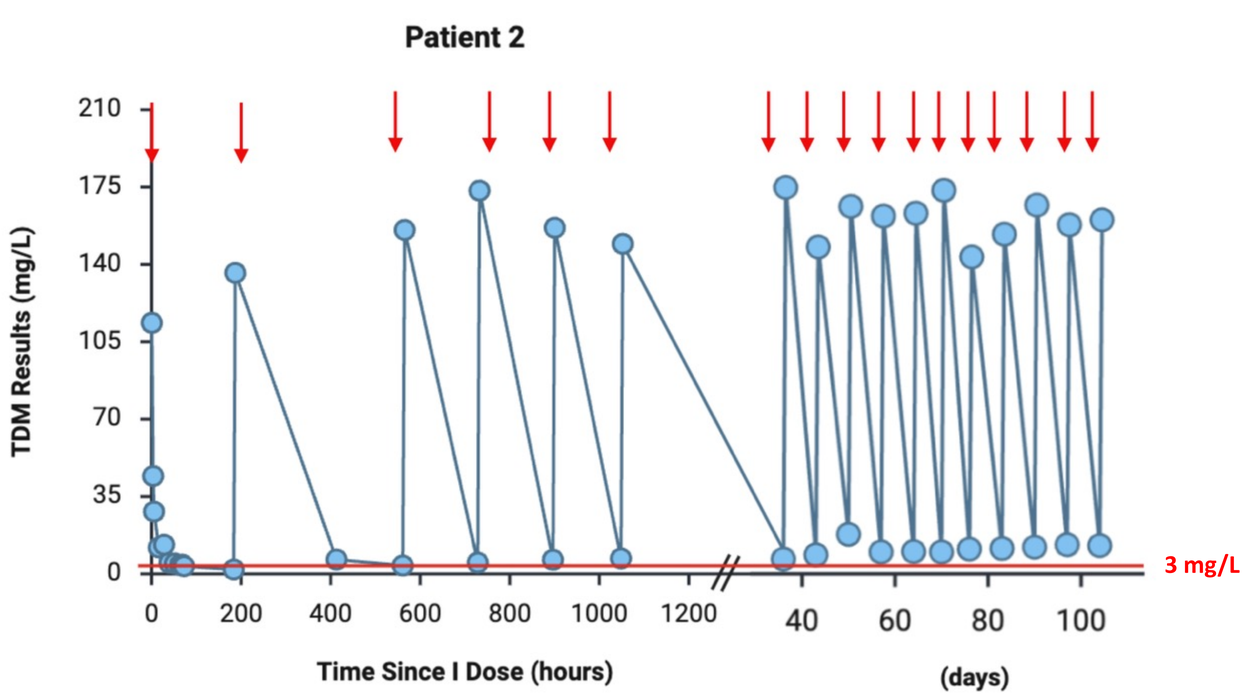

(1) Buonomo AR, Cattaneo L, Viceconte G, Calabria F, Di Troia G, Di Fusco A, Mula J, Cozzolino A, Ametrano L, D'Avolio A, Gentile I. Long-term oritavancin therapy for shoulder prosthetic joint infection: A case guided by therapeutic drug monitoring (TDM). IDCases. 2024 Oct 31;38:e02105. doi: 10.1016/j.idcr.2024.e02105. PMID: 39582750; PMCID: PMC11584596.
Figures were edited with Biorender.com

Results.

- **Case 1:** An 88-year-old male with chronic vancomycin-resistant *E.faecium* (VRE) PJI of the arthrodesis of the knee, uneligible for surgical revision, discontinued linezolid due to severe anaemia. No microbiological or clinical evidence of recurrence was observed. Treatment was complicated by PICC-related bloodstream infection and by a probable infusion-related adverse event (isolated febrile episode after the fourth infusion). Oritavancin was discontinued and linezolid successfully re-introduced (Figure 1).
- **Case 2:** A 74-year-old woman with complex post-traumatic VRE FRI and PJI involving tibial hardware and knee prosthesis experienced neurological toxicity on linezolid suppressive therapy. Oritavancin was initiated. Early outpatient follow-up showed clinical stability, and no acute drug-related toxicity (Figure 2) up to 17 drug administrations until recurrence. Further evaluation identified *Pseudomonas aeruginosa* on repeat synovial fluid culture, and additional surgery was planned.
- **Cases 3 and 4:** Two men aged 55 and 64 years with osteomyelitis with hardware retention and PJI due to *E.gallinarum* and VRE developed skin rash during first oritavancin infusion, unresponsive to slower infusion rates; treatment was discontinued in both cases.

Across cases, PK profiles showed consistent exposure with levels falling to the 3 mg/L target within 1 week, supporting weekly dosing; only after the fifth infusion in Case 2 were higher levels achieved that might have allowed a longer interval (Figure 2).

The dynamic of the observed adverse events and the following tolerability to other (lypo)-(glyco)-peptides suggest infusion related problems rather than true allergic reactions.

Conclusions. TDM-guided oritavancin may represent a feasible off-label SAT option for selected patients with PJI/FRI due to non-*faecalis* enterococci. Tolerability and timing of injection remain key practical challenges. Larger prospective datasets with the new oritavancin formulation (tolerability) and more TDM assessments (timing) are warranted.

Table 1 – Demographics and clinical details of the four patients treated with oritavancin at our centre.

Abbreviations: AE – adverse event; F – female; FRI – fracture related infection; M – male; NA – not applicable; OM – osteomyelitis; PJI – prosthetic joint infection; VR – vancomycin resistant.

Sex	Age	Clinical condition	Bacterium	Dosage (mg)	Doses	Frequency	AEs	Timing of AEs	Other (lypo)-(glyco)peptides used without AEs
M	88	PJI	*E.faecium* VR	1200	3	Day 0, 7, 28	Fever	During third infusion	Yes (daptomycin)
F	75	FRI-PJI	*E.faecium* VR	1200	17	Weekly	None	NA	Yes (daptomycin)
M	55	Hardware-OM	*E.gallinarum*	1200	1	NA	Skin rash	End of first infusion	Yes (teicoplanin)
M	64	PJI	*E.faecium* VR	1200	1	NA	Skin rash	During first infusion	Yes (vancomycin)