Multidisciplinary Pain Control Including the use of Methadone in a Critical Trauma Patient with Unidentified Polysubstance Use

Michael Lu, BA; Taylor Bentz, MD; Anirudh Bhimavarapu, BS; Clara Goldberger, BS; Vincent Bargnes III, MD; Adrian Fischl, MD; Amruta Desai, DO, MPH, MBA
Department of Anesthesiology, Stony Brook Medicine, Stony Brook, NY

Introduction

Effective perioperative pain control in trauma patients is often complicated by limited history and individualized responses. We present a complex case of a young male with flail chest and multisystem trauma whose severe pain and agitation revealed previously unrecognized opioid use disorder (OUD). This case highlights methadone's role in managing both acute pain and withdrawal, and underscores the importance of a multidisciplinary approach in trauma care.

Case Description

A 28-year-old male presented by ambulance after being struck by a vehicle at 40 mph. He was intubated on arrival with limited history available. Imaging revealed a subarachnoid hemorrhage, flail chest from left rib fractures (1–10), and a ruptured spleen requiring emergent splenectomy. Initial analgesia with fentanyl and adjuncts proved inadequate. He later underwent video-assisted thoracoscopic surgery with decortication and rib plating. Preincision methadone and cryoablation improved pain control and facilitated extubation by post-op day 2. Shortly after, he developed agitation, autonomic instability, and worsening pain. Psychiatry diagnosed acute opioid withdrawal due to previously unrecognized opioid use disorder. Initiation of methadone maintenance led to rapid stabilization, improved analgesia, and eventual transition to buprenorphine prior to discharge.

Dual Clinical Challenge, Dual Therapeutic Opportunity

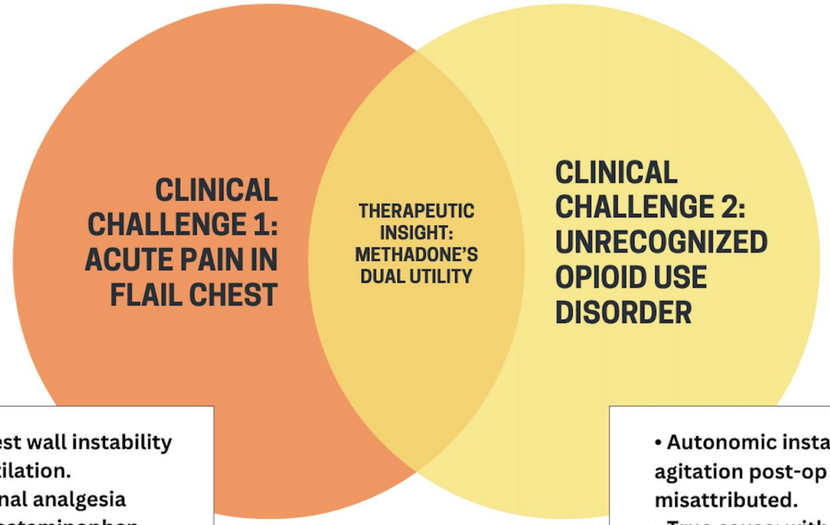

- **Severe chest wall instability limited ventilation.**
- **Conventional analgesia (fentanyl, acetaminophen, muscle relaxants) was inadequate.**
- **Pain control was essential for extubation, mobility, and recovery.**

Intraoperatively: long-acting opioid + NMDA antagonism → prolonged analgesia, reduced short-acting opioid needs.

Postoperatively: bridged to inpatient methadone maintenance → stabilized withdrawal, improved comfort, paved path to buprenorphine transition.

- **Autonomic instability and agitation post-op was initially misattributed.**
- **True cause: withdrawal from unrecognized OUD (positive Utox, clinical picture).**
- **Delay in diagnosis exacerbated patient suffering and recovery.**

Stony Brook Medicine

24th Annual Pain Medicine Meeting
November 13-15, 2025 | Austin, TX
50 ANNIVERSARY ASRA PAIN MEDICINE

Intraoperative Management

- Underwent video-assisted thoracoscopic surgery (VATS) with decortication and rib plating to facilitate extubation.
- Intraoperative analgesia:
  - Cryoablation by surgical team
  - 15 mg methadone, 100 mcg Fentanyl, 3.5 mg Hydromorphone
  - Intravenous 800 mg ibuprofen, Q6H acetaminophen peri-op

Postoperative Management

- Extubated on Post-op Day 2 with improved chest mechanics and pain control.
- Subsequently developed worsening pain, agitation, and autonomic instability.
- Psychiatry consult diagnosed acute opioid withdrawal due to unrecognized opioid use disorder.
- Started on inpatient methadone maintenance, leading to:
  - Clinical stabilization
  - Improved analgesia
  - Weaned off short-acting opioids
- Later transitioned to buprenorphine prior to discharge to minimize risk of relapse

Discussion

Flail chest trauma demands effective analgesia to support ventilation and facilitate extubation. In this case, undiagnosed OUD in the setting of an unidentified motor vehicle trauma victim complicated pain management and delayed withdrawal recognition. Methadone, a long-acting μ-opioid receptor agonist and NMDA antagonist, played a dual role in managing both acute pain and opioid withdrawal.

This case highlights the anesthesiologist's evolving role in trauma care and the value of early interdisciplinary collaboration in medically complex patients.

References available on request. Thank you.