Prosthetic Management of Palatally Positioned Implants in the Atrophic Maxilla: Clinical Report.

Jacqueline L. Martinez, DDS [1]; Sebastian Graca, DMD [2];Dima Ghunaim, DDS, MS, FACP, FAAMP [1]

[1] Advanced Education Program in Prosthodontics, University of Illinois Chicago COD
[2] Department of Oral and Maxillofacial Surgery, University of Illinois Chicago COD

Abstract

In a severely atrophic maxilla, palatally positioned implants can often be a trade-off when seeking fixed solutions. Zygomatic implants expand the range of treatment options offered to edentulous patients with significant atrophy. The focus is on overcoming surgical and prosthetic challenges to achieve aesthetic and functional success in dual-arch fixed complete therapy.

Initial Presentation

- A 62-year-old female with terminal dentition, failing implants and a severely resorbed maxilla presents seeking fixed solutions.
- CC: “I have been seen by multiple dental specialists. I got referred here.”
- Generalized bone resorption and pneumatized sinuses.

Diagnostic Tools

- Comprehensive examination and medical history.
- Intra-oral scans and photographs.
- CBCT imaging.
- Mounted cast.
- Interim denture fabrication for surgical planning.

Treatment Plan

- Extractions, Conventional CD fabrication, surgical planning.
- Combination of axial and zygomatic implants, custom titanium bar and zirconia sleeve.

Outcomes

- Patient restored with a fixed prosthesis, improving function.
- Eliminate the need for additional grafting procedures.
- Customized contoured palatal bar to improve speaking space and reduce thickness.

Diagnosis and Treatment Planning




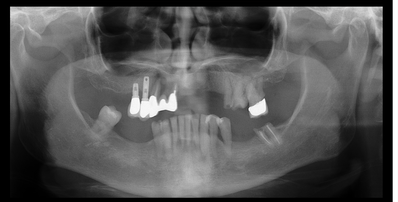

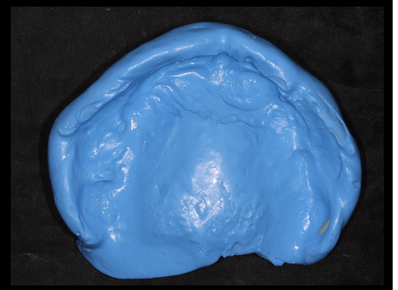
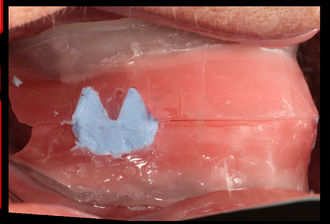


Surgical Phase


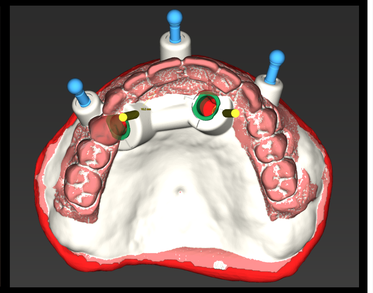
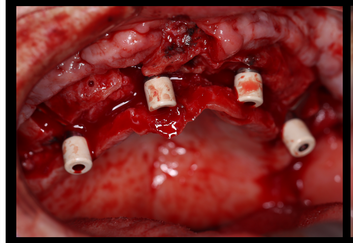
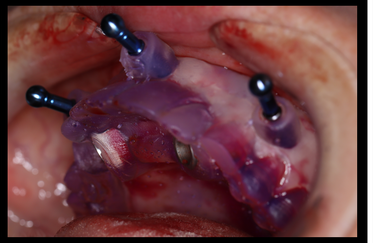




Prosthetic Phase






