An Evaluation of Soft-tissue Procedures in the Long-term Management of Patients with Syndromic Craniosynostosis

USC Plastic & Reconstructive Surgery

Children's Hospital LOS ANGELES

Tayla Moshal, BS; Idean Roohani, BS; Marah I Jolibois, MS; Sasha Lasky, BS; Eloise Stanton, BS; Erin M Wolfe, MD; Naikhoba CO Munabi, MD, MPH; Jeffrey A Hammoudeh, MD, DDS; Mark M Urata, MD, DDS

Background

- Skeletal craniofacial operations to treat different syndromic craniosynostoses are frequently discussed in the literature.
- However, soft-tissue procedures required to normalize facial appearance along these patients' care timelines are less well described.
- This study evaluated and compared the secondary soft tissue surgeries necessary for patients with various craniosynostosis syndromes.

Methods

- Retrospective review of patients with syndromic craniosynostosis treated at a tertiary children's hospital from 2004–2023.
- Soft tissue surgeries included:
  - ❖ Lateral and medial canthopexy
  - ❖ Ptosis reconstruction
  - ❖ Eyebrow elevation
  - ❖ Septorhinoplasty
  - ❖ Otoplasty
  - ❖ Scar revision
  - ❖ Scalp reconstruction
  - ❖ Fat Grafting
- Statistics:
  - Descriptive statistics, chi-squared, and independent t-tests analyzed differences in soft tissue procedures between craniofacial syndromes

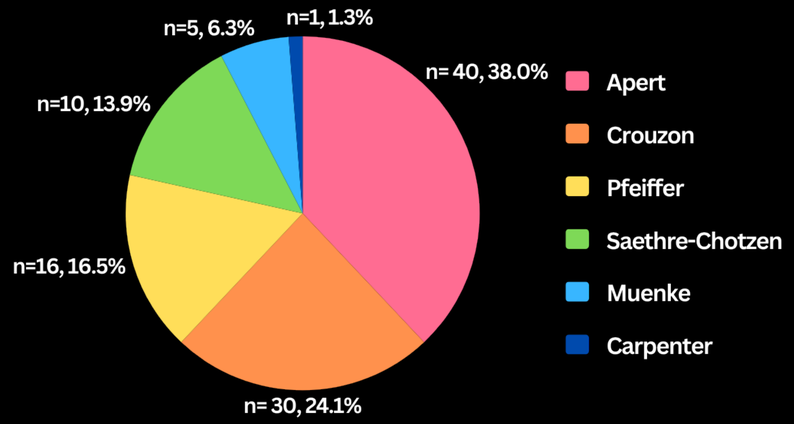

Figure 1. Syndromic Craniosynostosis Diagnoses

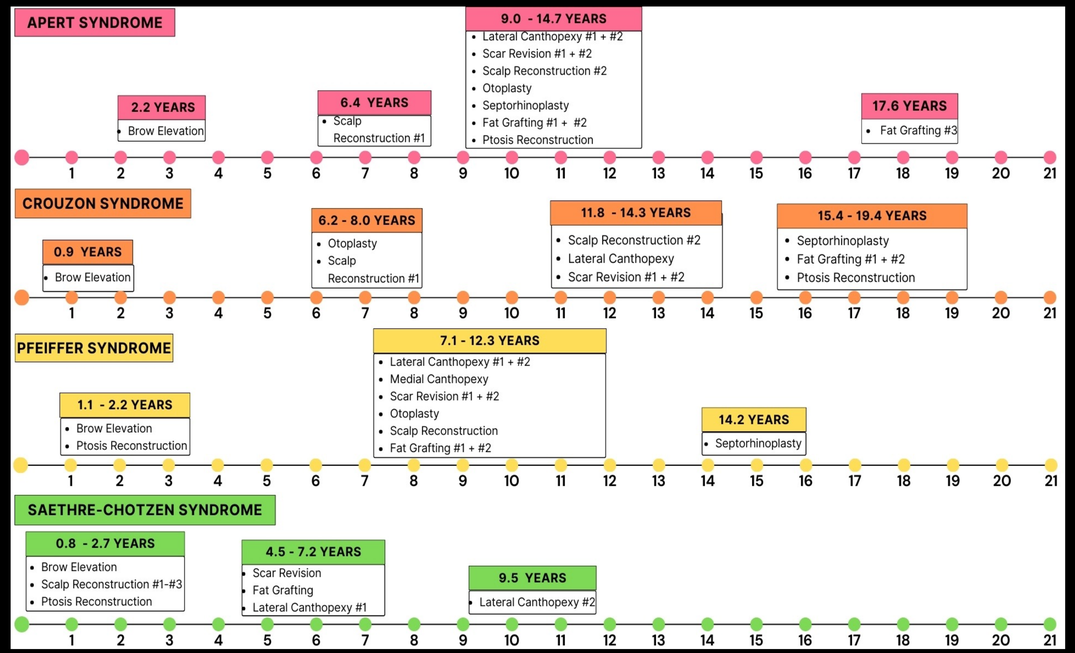

Figure 2. Timeline of Soft-Tissue Procedures in Syndromic Craniosynostosis

Results

- n=103 (Figure 1; Syndromic Diagnoses)
- Mean follow-up: 7.7±5.7 years
- 93 patients (90.3%) underwent ≥1 soft tissue procedure (mean = 3.6±3.3)
- Significant differences in rates of:
  - ❖ Brow elevation:
    - Saethre-Chotzen (63.6%) > Crouzon (25.8.%, p=0.034).
  - ❖ Scalp reconstruction:
    - Pfeiffer (50.0%) > Apert (32.5%, p=0.039), Crouzon (22.6%, p=0.007), and Muenke (0.0%, p=0.015).
  - ❖ Septorhinoplasty:
    - Crouzon (29.0%) > Apert (0.0%, p<0.001) and Saethre-Chotzen (0.0%, p=0.044).
- No differences in other soft tissue procedures
- Figure 2 displays soft tissue procedures timelines

Conclusion

- Soft tissue procedures were very common among patients with syndromic craniosynostosis.
- Rates of brow elevation, scalp reconstruction, and septorhinoplasty varied significantly by syndrome.
- These results may help surgeons counsel patients on anticipated surgical procedures necessary for comprehensive craniofacial reconstruction.
- Continued research is encouraged, and treatment should remain tailored to each patient's reconstructive needs.